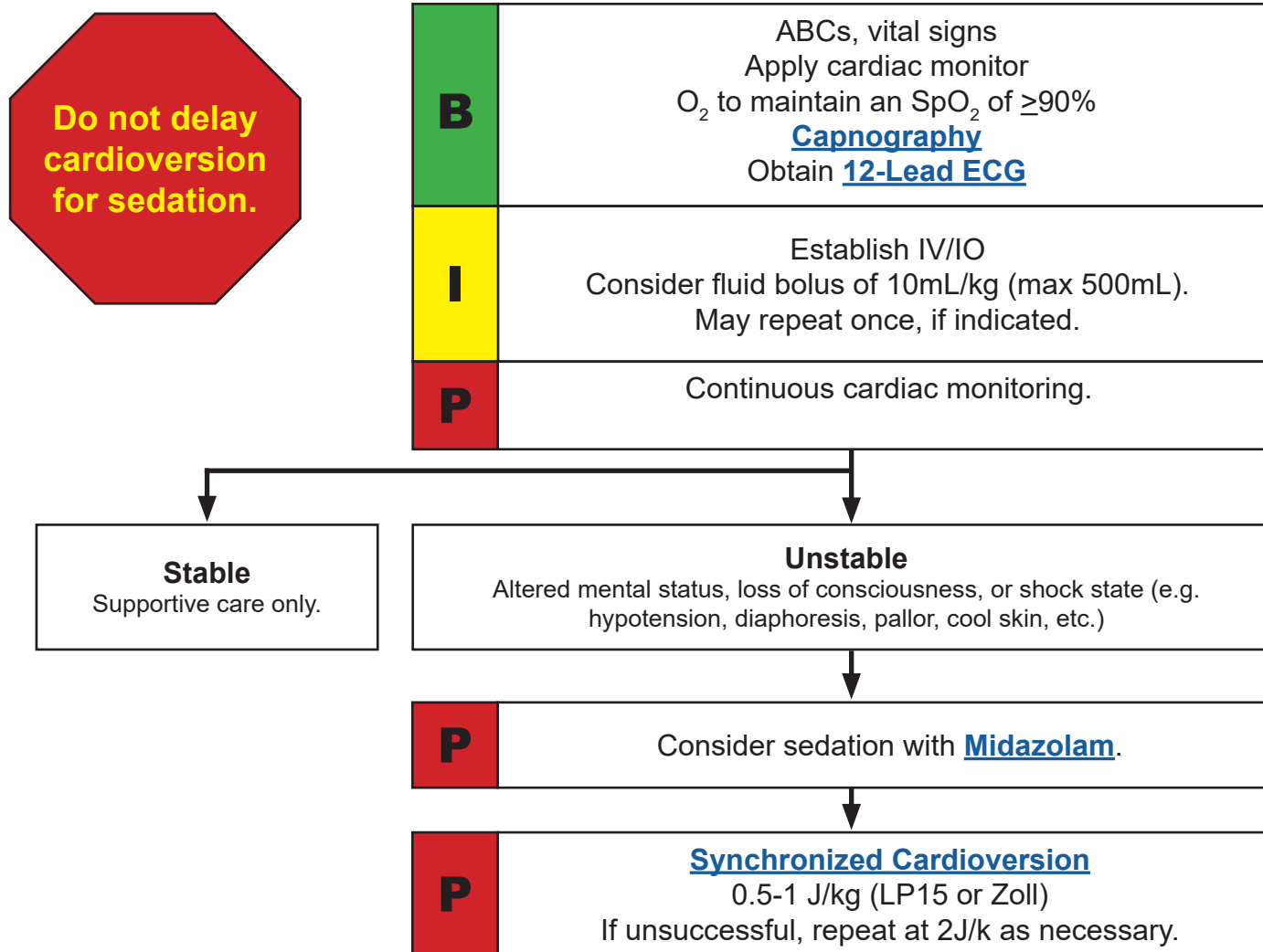


Pediatric Wide Complex Tachycardia - Monomorphic

Designation of Condition: The patient will have a pulse and show sustained ventricular tachycardia (wide QRS >0.12 sec) on the monitor. Polymorphic VT has QRS complexes that are different in shape and amplitude. Torsades de Pointes is a common type of polymorphic VT and is associated with long QT intervals.



KEY POINTS

Ventricular tachycardia is relatively uncommon in pediatric patients, but may be seen in children who have had cardiac surgery or have cardiomyopathy or myocarditis. Other causes of VT include: Long QT syndrome, electrolyte imbalances and drug toxicity. Symptoms can range from asymptomatic to cardiovascular collapse.